

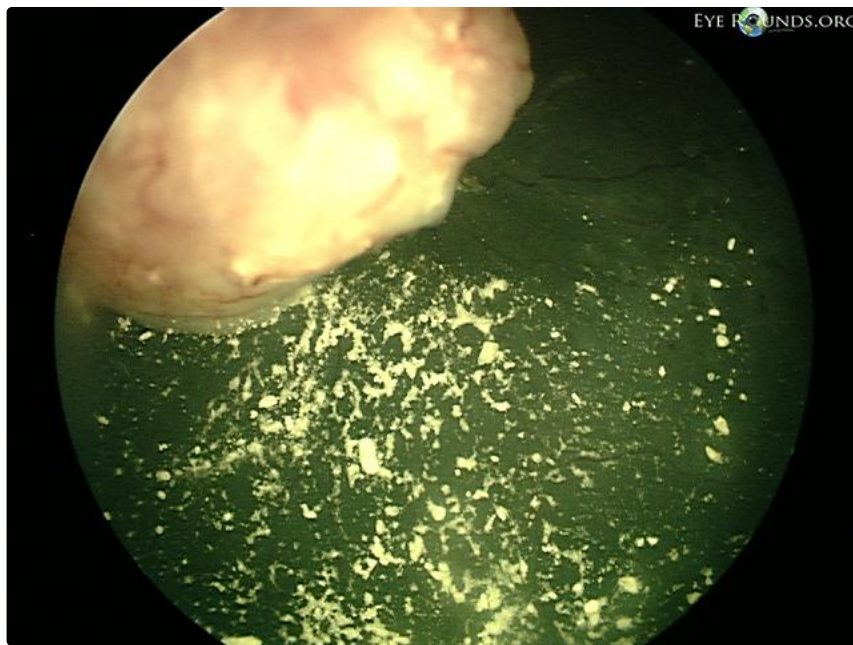
Vitreous seeding from retinoblastoma

Category(ies): Pediatrics, Vitreous

Contributor: [Jesse Vislisel, MD](#); [Kevin Gertsch, MD](#)

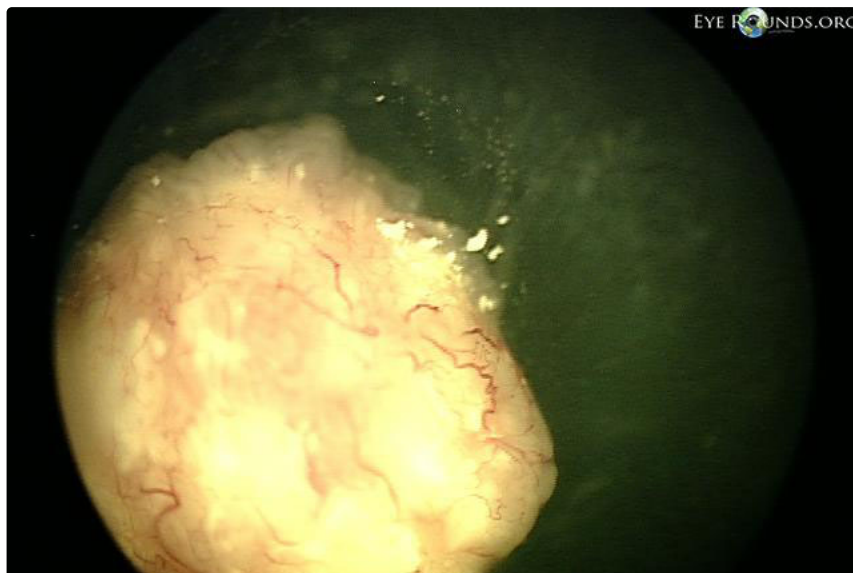Photographer: Kevin Gertsch, MD

Retinoblastoma is a neuroendocrine tumor that occurs in young children. The tumors may present with vitreous seeding, or free-floating buds of tumor cells within the vitreous.



[Enlarge](#)

[Download](#)





[Enlarge](#) [Download](#)

Reference:

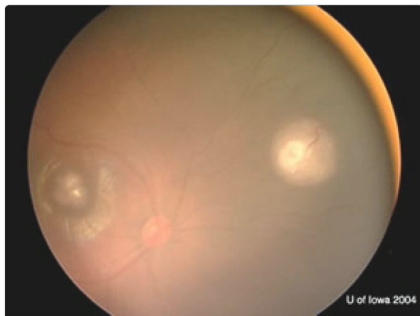
Image Permissions:



Ophthalmic Atlas Images by EyeRounds.org, The University of Iowa are licensed under a [Creative Commons Attribution-NonCommercial-NoDerivs 3.0 Unported License](https://creativecommons.org/licenses/by-nc-nd/3.0/).



Related Articles



[Related Case: Retinoblastoma](#)

Address

University of Iowa
Roy J. and Lucille A. Carver College
of Medicine
Department of Ophthalmology and
Visual Sciences
200 Hawkins Drive
Iowa City, IA 52242

[Support Us](#)

Legal

Copyright © 2019 The University of
Iowa. All Rights Reserved
[Report an issue with this page](#)
[Web Privacy Policy](#) |
[Nondiscrimination Statement](#)

Related Links

[Cataract Surgery for Greenhorns](#)
[EyeTransillumination](#)
Gonioscopy.org
[Iowa Glaucoma Curriculum](#)
[Iowa Wet Lab](#)
[Patient Information](#)
[Stone Rounds](#)
[The Best Hits Bookshelf](#)

**EyeRounds Social
Media**

Follow



Receive notification of new cases,
[sign up here](#)
[Contact Us](#)
[Submit a Suggestion](#)